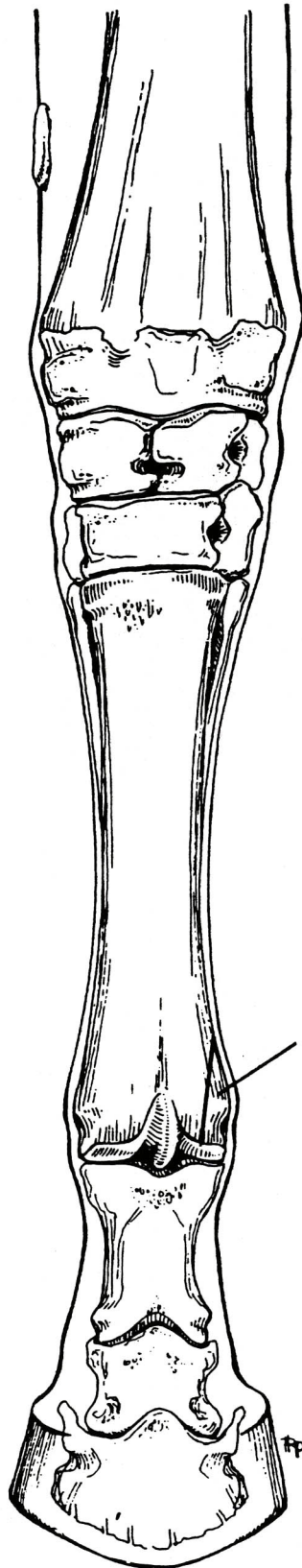


# Front Limb: front skeletal view, showing condylar fracture



Condylar Fracture

